

**926. Outbreak of Invasive Nontuberculous *Mycobacterium* (NTM) Infections Associated With a Pediatric Dental Practice**

Jasjit Singh, MD<sup>1</sup>; Kathleen O'Donnell, MPH<sup>2</sup>; Negar Ashouri, MD<sup>1</sup>; Felice C Adler-Shohet, MD<sup>1</sup>; Delma Nieves, MD<sup>1</sup>; M. Tuan Tran, PharmD<sup>3</sup>; Antonio Arrieta, MD, FIDSA<sup>1</sup>; Lisa Tran, DDS, MD<sup>4</sup>; Michele Cheung, MD MPH<sup>2</sup> and Matthew Zahn, MD, FIDSA<sup>2</sup>, <sup>1</sup>Infectious Diseases, CHOC Children's Hospital, Orange, California, <sup>2</sup>Epidemiology and Assessment, Orange County Health Care Agency, Santa Ana, California, <sup>3</sup>Pharmacy Services, CHOC Children's Hospital, Orange, California and <sup>4</sup>Surgery, CHOC Children's Hospital, Orange, California

**Session:** 113. Healthcare Epidemiology: Outbreaks!

Friday, October 5, 2018: 8:45 AM

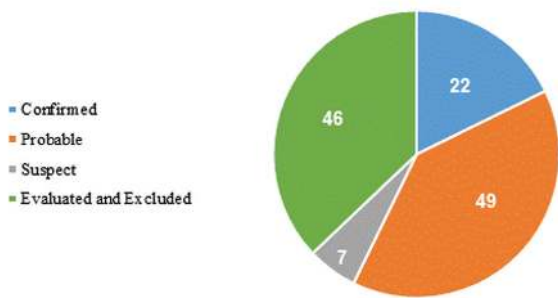
**Background.** In 2016, an Orange County, California, pediatric dental clinic's contaminated water system led to the largest outbreak of odontogenic NTM infections yet described.

**Methods.** Mandatory reporting and active case finding directed by County Public Health were conducted in collaboration with community Pediatric Infectious Disease physicians for patients who underwent pulpotomy at Dental Clinic A from January 1 to September 6, 2016. Confirmed cases were those with positive NTM culture. Probable cases were those with multiple pulmonary nodules on computed tomography (CT), necrotic bone or osteomyelitis seen at surgery, or pathology with positive acid-fast bacilli stain, granulomatous inflammation or chronic osteomyelitis. Clinical data was collected from medical records.

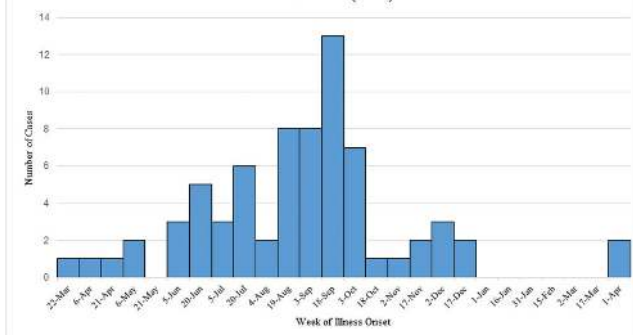
**Results.** Of 1,089 patients at risk, 71 cases (22 (31%) confirmed and 49 (69%) probable) (Figure 1) had been identified as of March 19, 2018 (Figure 2). Median case age was 6 years (range 2–11 years). Symptoms began a median of 85 days (range 1–409 days) after pulpotomy (Figure 3). Pain and/or swelling on admission were reported in 79%; 21% were asymptomatic. CT findings included 49/70 with abnormalities of the mandible or maxilla, 13/70 with lymphadenopathy, and 19/68 with pulmonary nodules. Only 6/60 had erythrocyte sedimentation rate >40 mm/hour. Of 71 cases, 70 were hospitalized and underwent surgical debridement, for an average of 8.5 inpatient days (range 1–60 days); 23 had >1 hospitalization and 26 required >1 inpatient surgery. Permanent teeth were lost in 45/65 (range of 1–6 teeth lost). Intravenous antibiotics were administered to 32 cases for a median length of 137 days (range 113–282 days). Clofazimine was obtained for 29/32 cases as part of the regimen. Medical therapy was complicated by peripherally inserted central catheter malfunction/replacement/infection (18/27), rash (2/27), neutropenia (12/27), and elevated creatinine (7/27). All treated children showed evidence of jaw healing with resolved or improving lung nodules at 1-year follow-up.

**Conclusion.** This is the largest outbreak of invasive NTM infections seen associated with a pediatric dental practice. While infections were indolent, patients suffered medical and surgical consequences of treatment. Enhanced national dental water quality standards are needed to prevent future outbreaks.

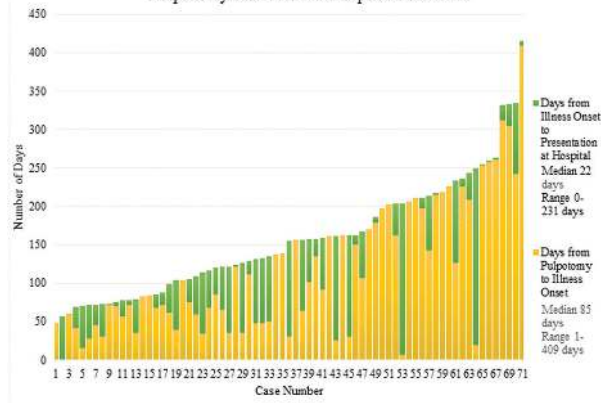
**Figure 1. Case Status Assignment for 124 Children Evaluated for Nontuberculous Mycobacterial Infection**



**Figure 2. Dental Outbreak Cases by Onset Date 3/23/16-4/02/17 (N=71)**



**Figure 3. Individual Case Progression Pulpotomy Procedure to Hospital Admission**



**Disclosures.** A. Arrieta, Melinta Therapeutics: Investigator, Research support

**927. Tap Water Avoidance Decreases Rates of Nontuberculous Mycobacteria in Intensive Care Units**

Arthur W. Baker, MD, MPH<sup>1,2</sup>; Becky Smith, MD<sup>1,2,3</sup>; Daniel J. Sexton, MD, FIDSA, FSHEA<sup>1,2</sup>; Kirk Huslage, MSPH, BSN, RN, CIC<sup>2,3</sup>; Jason E. Stout, MD, MHS<sup>1</sup>; Deverick J. Anderson, MD, MPH, FIDSA, FSHEA<sup>1,2</sup>; Rebekah W. Moehring, MD, MPH<sup>1,2</sup>; Christopher Hostler, MD, MPH<sup>1,2</sup> and Sarah S. Lewis, MD MPH<sup>1,2,3</sup>, <sup>1</sup>Division of Infectious Diseases, Duke University School of Medicine, Durham, North Carolina, <sup>2</sup>Duke Center for Antimicrobial Stewardship and Infection Prevention, Durham, North Carolina and <sup>3</sup>Infection Prevention and Hospital Epidemiology, Duke University Medical Center, Durham, North Carolina

**Session:** 113. Healthcare Epidemiology: Outbreaks!

Friday, October 5, 2018: 8:45 AM

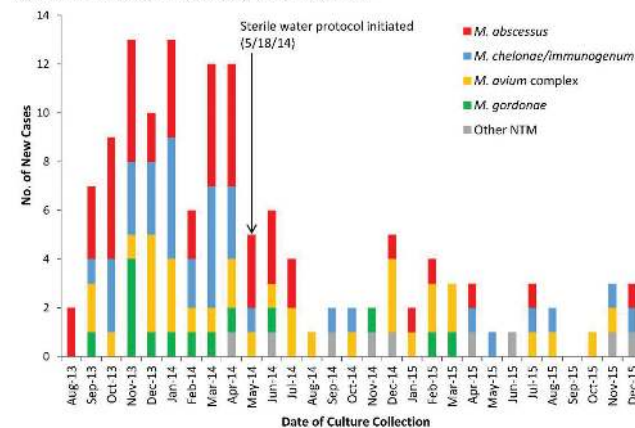
**Background.** We recently investigated a clonal outbreak of *Mycobacterium abscessus* molecularly linked to a colonized water supply at a new hospital addition. Use of sterile water instead of tap water for patient care in ICUs successfully mitigated the respiratory phase of the outbreak. We hypothesized that avoidance of tap water would also be associated with decreased respiratory isolation of other nontuberculous mycobacteria (NTM).

**Methods.** We analyzed all positive cultures for NTM obtained at our hospital from August 2013 through December 2015. The pre-intervention outbreak period was defined as August 2013 through May 2014; the tap water avoidance intervention period was defined as June 2014 through December 2015. NTM isolation was defined as a positive culture from a respiratory specimen obtained from an ICU patient on day 3 or later of hospitalization. We also performed AFB cultures of biofilms obtained from ICU water sources.

**Results.** NTM were isolated from 137 patients during 70,168 patient-days (figure). NTM isolation decreased from 41.0 patients/10,000 patient-days in the outbreak period to 9.9 patients/10,000 patient-days in the intervention period (IRR, 0.24; 95% CI, 0.17–0.34; P < .0001) (table). Incidence rates of the 4 most common NTM (*M. abscessus*, *M. chelonae/immunogenum*, *M. avium* complex, and *M. goodii*) also markedly decreased. Biofilm cultures were positive for at least 1 NTM isolate in 25 of 33 (76%) ICU water sources, including *M. abscessus* (n = 11, 33%), *M. chelonae/immunogenum* (n = 11, 33%), and *M. goodii* (n = 11, 33%).

**Conclusion.** The use of sterile water for ICU patient care substantially decreased NTM isolation from patient respiratory specimens, presumably reducing risk of symptomatic infection. Hospitals with endemic NTM should consider tap water avoidance for high-risk patients.

**Figure.** NTM isolated from the respiratory tract of ICU patients.\*



\*The intensive care units opened for patient care 7/29/2013.